_____

NAME

_____

DATE **Rec. #**

YOUR BLOOD PICTURE

A TRAVELOGUE FOR THE MICROSCOPIC JOURNEY INTO YOUR LIVING BLOOD

THE IDEAL BLOOD PICTURE

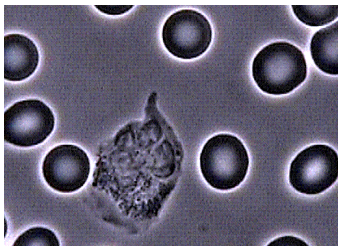

The red cells (technically corpuscles) are uniform in size and shape and appear as round circles on a gray background. The center of the cells are lightened somewhat and slightly off white in color. They reside freely in their own space, not overlapping or sticking together, but gently bouncing off each other.

The white cells are about as large as two red cells and have a rather grainy appearance with different characteristics depending on their type. They display many different shapes and some are active and moving, In normal blood there are about 700 red cells to every white cell.

The serum surrounding the cells is clear with some chylomicrons & globin particles dancing about & a scattering of platelets but without much cellular breakdown, bacteria, clots, or other undesired floating masses.

The microscopic view is a look at just one of the body's fluid compartments and is a qualitative reflection of your internal "biological terrain". For more understanding of these concepts, see the book "How You Rot & Rust" or read the Rot & Rust tutorial on the internet at www.biomedx.com

_____

Blood Type ___ O ___ A ___ B ___ AB

RED BALL TEST - When a drop of blood appears on the finger it should bead up. If the ball is absent it may indicate low protein due to:

-lack of protein in diet,
-poor digestion (lack of digestive enzymes),
-kidney problems,
-anemia (low blood iron.)

___ ball present ___ ball absent

___ color bright red ___ color dark red

Saliva pH _____ Blood Glucose _____

Hours Since Last Meal _____

NOTE: Contributing factors or causes as listed are items that may or may not be applicable to your own situation. Different items will apply from person to person and further dietary, lifestyle and health history will be needed to more correctly understand your own "blood picture".

KEY: 1 = MILD to 5 = SEVERE.
If not marked, condition insignificant or not found.

Red Blood Cells

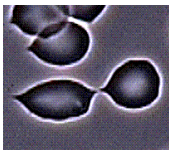

1 - DACRYOCYTES
Lemon/tear shapes.
1 2 3 4 5

2 - ROULEAU
Stacked RBC's.
1 2 3 4 5

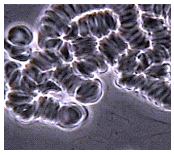

3 - AGGREGATION
"Blood Sludge".
1 2 3 4 5

Each of these indications (progressively worse) reflects a loss of "charge" of the RBC which causes them to stick together. Cells find it more difficult to transfer oxygen to tissues and to circulate freely. SIGNS: Fatigue, hard heart beat, BP off, many things. CAUSE: Too much cooked animal protein in diet, low digestive capacity and enzyme utilization, dehydration, diet not proper for blood type, consumption of processed foods, high sugar & carb intake. Alcohol. Minerals off. Inflammation marker.

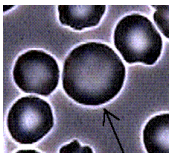

4 - ANISOCYTOSIS
Variation in RBC size.
Macrocytes - Big RBC's.
1 2 3 4 5
Microcytes - Small RBC's
1 2 3 4 5

Macrocyytes / Path >20%
SIGNS: Inability of RBC's to adequately carry oxygen - shortness of breath, fatigue, light headedness, anemia. CAUSE: Overall lack of good nutrition or assimilation which can lead to being low in vitamin B12, folic acid, fat soluble A&E vitamins. Connect these dots to poor digestion & possible lack of HCL, low bile flow, enzyme production. This could lead to lack of friendly intestinal bacteria...
Microcytes / Path > 20%
SIGNS: Anemia, low energy, tired. Bone problems, osteoporosis. Disintegration of RBC's into smaller vesicles could indicate more serious chronic issues or focal burden.
CAUSE: Low in iron, B12, folic acid, same as above.

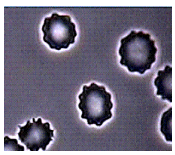

5 - POIKILOCYTES RBC bottle cap formations - Membrane corrugation. CAUSE: Lipid peroxidation, poor digestion of fats, excess PUFAs in diet, free radical stress: food additives, cigarettes - environmental chemicals, pesticides, Rx/street drugs, lowered anti-oxidant capacity. SIGNS: Poor circulation, low energy, accelerated aging...
1 2 3 4 5

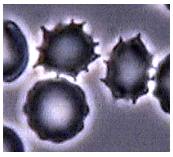

6 - ECHINOCYTES RBC's with sharp burrs, shrunken and spiked w/regularity, dying, Up to 1% normal, Path >20%.
CAUSE: Rx/street drugs, free radicals, toxins, alcohol, lack of good nutrition. Spleen stress.
SIGNS: Poor circulation, low energy, degenerative disease.
1 2 3 4 5

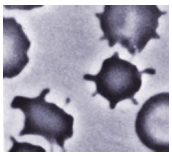

7 – ACANTHOCYTES
RBC's with burrs, spiked *irregularly*. >1% not normal. Path >10%
CAUSE: Rx/street drugs, free radicals, toxins, alcohol, lack of nutrition or malabsorption, liver and spleen stress. SIGNS: Poor circulation, low energy, anemia, degenerative disease.
1 2 3 4 5

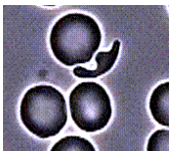

8 - SCHISTOCYTES RBCs broken membrane, fragile, fragments. Path > 20% CAUSE: Ingestion or inhalation of toxins, fumes, tobacco, drugs, oxidative stress—all stress the liver. SIGNS: Anemia, low energy, tired, degenerative disease.
1 2 3 4 5

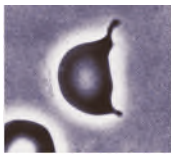

9 - KERATOCYTES RBCs with a horn appearance. Path > 5% CAUSE: DIC - Disseminated intravascular coagulation. The circulation is seeing internal coagulation which shouldn't be. Vascular prosthesis. SIGNS: Circulation issues, cold hands/feet, fatigue/anemia.
1 2 3 4 5

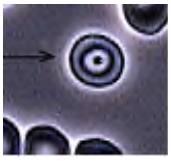

10 – CODOCYTES Target Cells RBCs whose membranes have collapsed on itself with dot in the center making it look like target. CAUSE: Possible low iron or disorganized cellular iron, bile insufficiency, liver issues. SIGNS: Anemia, increased cholesterol, passing gas.
1 2 3 4 5

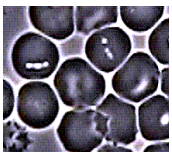

11 - LESIONS on RBCs
CAUSE: Internal bacterial blood elements that find a home in the cell due to overall altered pH/biological terrain. SIGNS: Anemia, tired, low energy, fatigue, auto-immune diseases.
1 2 3 4 5

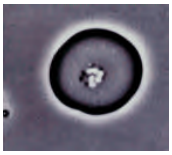

12 - RETICULOCYTES Premature larger than normal RBC's with remnants of nucleus. Up to 1% normal. CAUSE: Blood loss anemia (after hemorrhage) , fibroid tumors, iron deficiency, new to high altitudes. SIGNS: Tired.
1 2 3 4 5

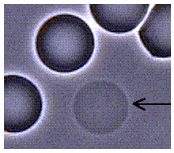

13– HEMOLYZED RBCs
Shadow or ghost cells. CAUSE: Premature red cell destruction from oxidative stress, drugs, alcohol, smoking. SIGNS: Low energy, depressed.
1 2 3 4 5

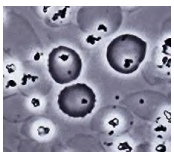

14 - HEINZ BODIES Granules in RBC's - damaged hemoglobin. CAUSE: Certain forms of Rx drugs, hemolytic anemia. SIGNS: Fatigue, low oxygen.
1 2 3 4 5

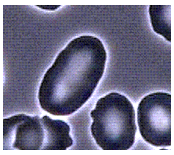

15 - OVALOCYTES Path >20% CAUSE: Lack of B12, folic acid, hormonal imbalance. SIGNS: Anemia, hormonal issues.
1 2 3 4 5

16 ____ Bites out of RBCs Viral activity.

17 ____ Protrusions from RBCs Gall bladder, bile, gas.

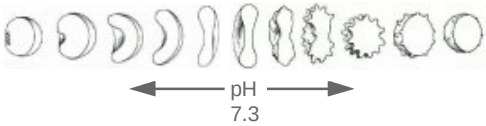

White Blood Cells

18 - WBCs FEWER than normal based on scan. (approx. 1wbc per every 700rbc) If healthy may be OK, if sick it could be problematical, indicates more catabolic.

___ below normal

19 - WBCs MORE than normal based on scan. CAUSE: Viral activity, bacterial infection, rods, L -form mononucleosis, mycoplasma, stress, lack of sleep, indicates more anabolic.

___ above normal

Elevated WBCs (Leukocytosis) after eating typically:

None from raw organic food.
Mild from stovetop or oven cooking.
Moderate from pressure cooked or canned foods.
Severe from proc. foods, candy, refined carbs, soft drinks.
Whopping from proc. meats & microwave cooking.

Granulocytes

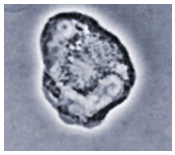

20 - NEUTROPHILS INACTIVE, round, granules not streaming. (Neutrophils ingest and destroy bacteria.) CAUSE: Altered blood pH, minerals off, low exercise, too much alcohol, sugar, yeast imbalance, SIGNS: Immune system deficient, reduced ability to destroy parasites, diseased tissue

1 2 3 4 5

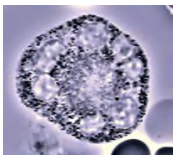

21 - HYPERSEGMENTED neutrophils 5+ lobes in nucleus. CAUSE: Low B12, folic acid, early bone marrow depletion, poor digestion, malabsorption. SIGNS: Possible anemia, reduced ability to destroy parasites, diseased tissue.

1 2 3 4 5

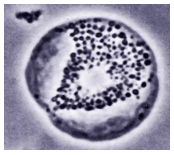

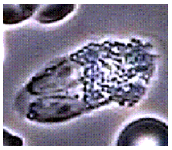

22 - EOSINOPHILS WBC w/moving granules which can be highly refractile, phagocytic. 2-5% is normal. EOs High. CAUSE: Parasites, drugs, smoking, second hand smoke, bone bruises, irritation, inflammation, menstruation. Anabolic. EOs with white edges indicate allergic reaction (allergies). Low EO count is catabolic.SIGNS: Irritation, soreness, inflammation, pain, aches, swelling, sinus congestion, drainage.

1 2 3 4 5

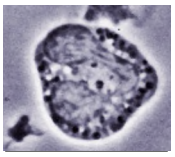

23 - BASOPHILS. Slow moving granules, low activity, usually non-phagocytic appearing. Release histamine, heparin. CAUSE: Allergies to inhalants - mold, cats, dust, pollen, perfume. Toxic kidneys, diuretics. SIGNS: Nose runs, sinus problems, flu, cold, stuffed up. Eyes weep, blur, sting, dry. Edema, water retention.

1 2 3 4 5

Lymphocytes

B & T-Cells

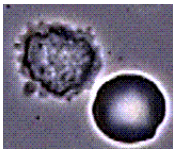

24 - LYMPHOCYTES excessive. CAUSE: Degenerative disease conditions, free radicals & toxins, lymph system fighting, environmental chemicals, pesticides, food additives, smog, EMFs, viral activity. SIGNS: Fatigue, low oxygenation.

1 2 3 4 5

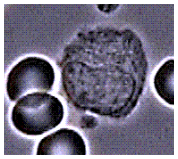

25 - LYMPHOCYTES too few CAUSE: Immune deficiency, radiation damage, free radicals, problems in bone, xrays.

1 2 3 4 5

26 - LYMPHOCYTE Cytoplasm damage. (White areas on edge.) CAUSE: Viral activity, low oxygen, immune deficiency

1 2 3 4 5

Platelets

Platelets are part of your blood clotting mechanism. When you cut yourself or experience vascular damage, platelets go to the area of the assault and bind together with fibrin so you don't bleed to death. Platelets can become excessively sticky in circulation.

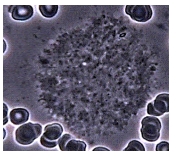

27 - PLATELET/THROMBOCYTE AGGREGATION. CAUSE: High triglycerides, excessive red meat, stress, caffeine, sodas, chocolate. SIGNS: Circulation, capillary blockage, blood clots, heart.

1 2 3 4 5

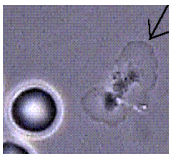

28 - SPREADING PLATELETS – Spreading membrane formations often seen around platelets like butterfly wings. CAUSE: It is a natural phenomenon of platelets to spread on a slide but it does not occur in all samples. Why some spread and others do not may be due to altered pH/biological terrain, internal toxicity, excess dietary PUFAs and carbohydrates.

1 2 3 4 5

Perspective of platelet count based on scan.

___ below normal ___ above normal

Crystal Formations

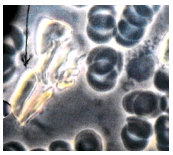

29 - CRYSTALS, cholesterol. Trapezoidal shapes. CAUSE: Poor digestion of fats, LDL high, (dangerous if LDL low). SIGNS: Blood pressure up, clogged arteries, plaque buildup.

1 2 3 4 5

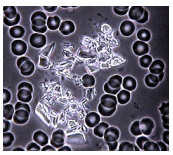

30 - CRYSTALS, triglycerides artherosclerotic plaque. Appears as broken glass. CAUSE: Poor digestion of fats, altered pH, low mineral charge.

1 2 3 4 5

31 - CRYSTALS, square, [circular]. CAUSE: Neurologic problems. [circ - immune system inactive/deficient, not removing toxins.] SIGNS: nervous, high strung, irritable, hyperactive, depressed, listless, aimless, headaches.

1 2 3 4 5

32 - CRYSTALS, bright colored (orange/red). CAUSE: Uric acid excess. SIGNS: Autoimmune diseases, arthritis, gout, poor lube, bacteria.

1 2 3 4 5

Blood Proteins

Three blood proteins are albumin, globulin and fibrinogen. A high albumin/globulin or A/G ratio is a sign of good health. We cannot see these proteins in the blood, but we can see fibrinogen when it begins to activate and turn to fibrin. Seeing fibrin strands develop in your picture, depending on speed and intensity, is a sign the blood might be a bit thick and this could be stressful for the liver and cardiovascular system in general.

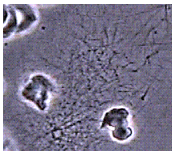

33 – FIBRIN FORMATIONS, fibrous (fibrinogen) needles in serum denote hyper-proteinemia, thicker blood, congestions, inflammation, liver stress, possible pH imbalance of the connective tissue. CAUSE: Toxins, drugs, alcohol, tobacco, excess protein... SIGNS: Indigestion, heartburn, bloating, gas, hard breathing upon exercise, fatigue, headaches, backaches. Autoimmune diseases.

1 2 3 4 5

Other Blood Elements

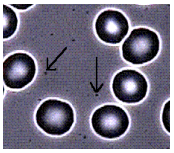

34 - PLASMA PARTICLES CAUSE: Normal blood elements which can be chylomicrons - fat particles - lipo-proteins, globin & cell organelles from cellular breakdown, L-Form bacteria. Which is which cannot be known through appearance alone.

___ Normal
___ Too few (anabolic)
___ Too many (fat or catabolic)

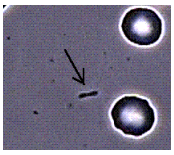

35 - BACTERIAL FORMS double spore, barbells, rod forms, can appear as streptococci (like a beaded necklace) or staphylococci (like hooked lego blocks), bacterial stages. Indicates immune stressors which if carried to extremes can compromise health. CAUSE: Immune insufficiency, leaky gut, terrain off. SIGNS: 1000 different things.

1 2 3 4 5

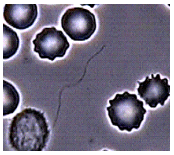

36 - MYELIN STRANDS Thin, wispy wormy looking moving filaments. CAUSE: Membrane breakdown from all cellular & sub-cellular particles. Generally results from pathologic separation of certain cellular constituents that have high proportion of lipids. Altered pH.SIGNS: Anything.

1 2 3 4 5

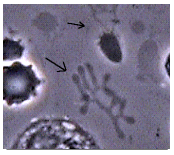

37 - MYELIN FORMATIONS Thicker, expansive, worm like, fungal appearance. CAUSE: Same as above. SIGNS: Could be anything, maybe more serious breakdown.

1 2 3 4 5

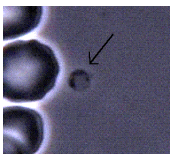

38 - PHOSPHOLIPID FORMS Dark gray circular forms. CAUSE: Phospholipids make up 25-30% of the dry weight of cell protoplasm. When cell death occurs, lipids are liberated and recombine to many diverse structures. They appear as bacterial spheres. Some health practitioners correlate this to mouth pathology and heavy metals. SIGNS: Could be anything, breakdown processes, muddled thinking, CNS issues.

1 2 3 4 5

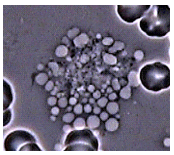

39 - PHOSPHOLIPID FORMS or **DISACCHARIDE FORMS** Light gray or white circular or globular forms. CAUSE: Same as above, platelet membrane pinocytosis, some health practitioners correlate these structures to yeast and sugar issues - and their contributing factors. SIGNS: Could be anything.

1 2 3 4 5

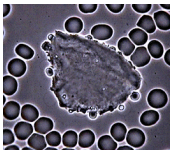

40 - PROTOPLAST/PLAQUE Forms that can have many appearances, like rocks, big fibrous particles, translucent, solid. CAUSE: A merging of all plasma colloids due to change of charge - from toxins, endo, exo, xeno - altered pH/ terrain. SIGNS: Circulation issues, fatigue, FOCI,degenerative disease potential.

1 2 3 4 5

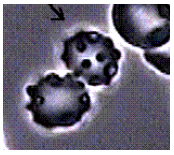

41 - MYCOPLASMA FORMS (Could also be lipid storage granules.) CAUSE: Altered pH, stealth infection, stress, lack of sleep, physical strain, overwork. SIGNS: Fatigue, aches/ pains, poor circulation, 1000 things…

1 2 3 4 5

This sheet is for health education only and is not intended to be used for any form of diagnosis, analysis, assessment, assay or clinical test/process. © 2011 **BIOMEDX**